



## Histomorphometric Study Based on Personal Medicine Effect of Propiconazole on Bone Growth Plate of Male Gerbil

Saber Kabiri-Samani<sup>1\*</sup>, Hamidreza Kabiri<sup>2</sup>

<sup>1</sup>Young Researchers and Elite Club, Shahrekord Branch, Islamic Azad University, Shahrekord, Iran.

<sup>2</sup>Young Researchers and Elite Club, Shahrekord Branch, Islamic Azad University, Shahrekord, Iran; Sina Borna Aria (SABA) Co., Ltd, Research and Development Center for Biotechnology, Shahrekord, Iran.

DOI: 10.22034/pmj.2022.700887

\*Corresponding author: Saber Kabiri-Samani, Young Researchers and Elite Club, Shahrekord Branch, Islamic Azad University, Shahrekord, Iran. Email: sabaco92@yahoo.com.

Submitted: 2022-07-28

Accepted: 2022-11-19

### Keywords:

Growth plate  
Bone tissue  
Propiconazole  
Oxidative stress  
Rat

©2022. Personalized Medicine Journal

### Abstract:

Propiconazole is a systemic fungicide from the triazole group used to control a wide range of diseases. This poison causes cellular, genetic and metabolic damage in animals. A bone is a hard tissue whose content is constantly changing. Longitudinal growth of the bone occurs through the growth plate, which is a cartilaginous structure at the end of the body's long bones. During puberty, while the growth plate closes (ossifies), the longitudinal growth of the bone stops. This study aimed to investigate propiconazole's effect on growth plate width changes (including the area of proliferating cells and the area of hypertrophied cells) in immature rats. This experimental study was conducted on 12 immature male Wistar rats randomly divided into control and propiconazole groups. The treatments were done by oral gavage for 28 days. On the 28th day, the dead animals and the left leg femur were separated for histomorphometric studies of the growth plate width of the femoral epiphysis. Investigations were carried out by (Rasband Wayne, 40g.1. ver, ImageJ, USA, NIH), and the significance of the results was done by ANOVA analysis of variance and Tukey's test. The width of the growth plate in the propiconazole group had a significant decrease compared to the control group ( $P = 0.0126$ ), which is a decrease in the width of the proliferating area ( $P < 0.001$ ) and an increase in the width of the hypertrophied area ( $P = 0.016$ ). Propiconazole leads to a decrease in the width of the growth plate of the femoral epiphysis of immature rats. It can be a factor in disrupting the process of longitudinal bone growth and premature closure of the growth plate.

## INTRODUCTION

Bone tissue is an active and dynamic tissue whose internal microscopic structure is constantly changing and transforming by bone cells (osteoblasts and osteoclasts), plate growth, (remodeling structure). Cartilage is highly organized between the epiphysis and bone (1). The diaphysis is at the end of the long bones of the body, which is divided into horizontal areas of chondrocytes (chondrocytes) in different stages of differentiation (proliferating cells and hypertrophied cells) (2, 3).

Longitudinal bone growth results from the proliferation and differentiation of chondrocytes of the growth plate, which affects the genetic factors, hormones, growth factors, environment, and nutrition. Growth plates are closed with puberty (the matrix of chondrocytes becomes bone), and the longitudinal

growth of bone ends (4-6). Growth plates in mice remain open for an extended period until after sexual maturity and perhaps throughout the natural life span of the animal. Propiconazole is a systemic fungicide from the triazole group, which is used to control a wide range of fungal diseases in agriculture, such as rice sheath blight, wheat rust disease, and wheat spike Fusarium (3, 7).

Propiconazole causes toxicity in animals and types of tissues, leaves a wide range of biochemical effects in non-lethal doses, and can cause cellular, genetic and environmental damage (8, 9). Few studies have been done on the effect of propiconazole on the bone and cartilage tissue of the skeletal system (10-12). During the analysis of propiconazole on chicken and quail embryos, the teratogenic effects of this poison on cartilage and bone growth have been reported (13,

19). Also, in the study of a family that was mistakenly exposed to this poison at home, it was found that propiconazole, in addition to neurotoxicity and endocrine, had destructive effects on the development of the skeletal system of the children of this family, including delayed calcification. He pointed out the delay in bone growth, cyst growth in bones, pathological fractures and lack of response to bone grafting in the children of this family (14-18).

In response to the question of whether contact with propiconazole poison can lead to premature closure of the growth plate, followed by delay or reduction of longitudinal bone growth, the present study aims to investigate the effect of propiconazole poison on the epiphyseal cartilage (growth plate) of rats. It was done prematurely.

## MATERIALS AND METHODS

### *Provision of animals*

In this experimental study, 12 four- to five-week-old Wistar male desert rats (average weight 100 gr) were obtained from the Faculty of Pharmacy of Tehran University and transferred to the animal research laboratory.

### *Grouping and storage conditions*

Mice were randomly divided into two groups of six, control and propiconazole. All the experiment stages were carried out following the principles of bioethics in the case of laboratory animals. During the research period, the rats were placed under the same and standard conditions in terms of light (12 hours of light and 12 hours of darkness), proper ventilation and temperature ( $22 \pm 2$  ° C), and enough water and traditional food (chow rat standard) in Their choice was made.

### *Determination of drug concentration*

The concentration of propiconazole used in this study was chosen as 30 kg/mg based on previous studies (11, 17, 18). The injection of 30 kg/mg dose and even doses of 25, 15, and 10 kg/mg led to the death of animals. The reason for this could be the young age and immaturity of the tested mice; as a result, they could not tolerate the dose they consumed. Therefore, the dose of 5 kg/mg, the non-lethal dose of propiconazole, were considered in this research.

### *Preparation of medicinal dilutions*

Propiconazole 95% from Shanghai Tosco Chemical Co., Shanghai (China) was used to prepare the dosage. Dilution was done using the formula  $C_2V_2=C_1V_1$  and corn oil as a solvent. The volume of propiconazole 0.5 ml with a dose of 5 mg/kg for the propiconazole group and the same volume of corn oil for the control group was administered by oral gavage for 28 days at 10 am (20, 21).

### *Sampling of tested animals*

After completing this period, the animals were killed in a desiccator following ethical principles. The left leg's femur was immediately removed for histological studies (growth plate histomorphometry) to fix the cells in 10% formalin for at least 24 hours. The time was set. In order to soften the bone tissue (decalcification), a 7% nitric acid solution was used for five days and nights, and the solution was replaced daily. After the decalcification, it was used to remove the effect of nitric acid from 5% sodium sulfate solution and to remove the effect of sodium sulfate from running water for 24 hours (22, 32).

### *Histopathological study*

In order to investigate the tissue changes resulting from the treatments, histomorphometric studies were performed on the slides prepared from the growth plate tissue of the left leg's epiphysis region of the femur and with the help of hematoxylin-eosin (E&H) staining. In this staining, which is a general staining, the nuclei appear blue to purple, and the cytoplasm and connective fibers appear pink (30, 31).

### *Measurement of epiphyseal growth plate width*

In order to measure the width of the epiphyseal growth plate in each group, the width in six tissue sections different from that group and in three regions of each section using ImageJ software, version 1.40g (Wayne Rasband, USA, NIH) and on the prepared photographs. The average of these values was measured from microscopic sections and considered each group's width of the epiphyseal growth plate. The proliferating cells' width and the area of hypertrophied cells on the growth plate were also measured in the same order in each group (23).

### *Statistical analysis*

One-way ANOVA was used for statistical calculations using GraphPad Prism® software, version 6 (La Jolla, CA 92037, USA). The averages were calculated as  $SEM \pm Mean$ , and their comparison was made with Tukey's multiple comparisons test. A significance level of  $P < 0.05$  was considered. Also, the graphs were drawn with the help of Microsoft Office Excel 2007 software.

## RESULTS

### *Investigation of growth plate width*

The average width of growth plaque, proliferating area, and hypertrophied area in the propiconazole group was 0.4278, 0.2317, and 0.2383 mm, respectively. These values in the control group were 0.9200, 0.3417, and 0.1950, Table (1).

Investigating the average width of the epiphyseal growth plate

Examining the average width of the epiphyseal

**Table 1.** The average width of the growth plate, the area of proliferating cells of the growth plate, and the area of hypertrophied cells of the growth plate in the propiconazole group and the control group.

Variables	Propiconazole group (standard deviation ± mean)	Control group (standard deviation ± mean)	P value
Plaque growth width (mm)	4278,1212 ± 0.0	9200,3787 ± 0,0	0126,0
The width of the growing area of the growth plate cells (mm)	2317,03125 ± 0,0	3417,02401 ± 0,0	0001,0
The width of the area of hypertrophied cells of the growth plate (mm)	2383,02927 ± 0,0	1950,02258 ± 0,0	0166,0

growth plaque of the tested groups showed a significant decrease ( $P=0.0126$ ) of the growth plaque width in the propiconazole group compared to the control group (Figure 1, 2, 3). The tested groups showed a significant decrease ( $P<0.0001$ ) in the width of this area in the propiconazole group compared to the control group ( $P<0.0166$ ). the width of this area was observed in the propiconazole group in comparison with the control group (Figure 3).

## DISCUSSION

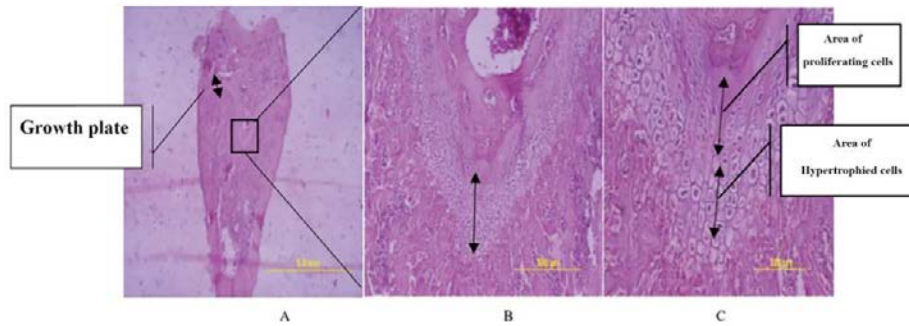
The data obtained from the calculation of the epiphyseal growth plate width of the tested groups showed that propiconazole significantly reduced the width of the growth plate (24). In the propiconazole study on chicken and quail embryos, the teratogenic effects of this poison on the growth of cartilage and bones were reported by researchers (24). The propiconazole teratogenic effects include the reduction of the growth of the skeletal elements of the leg and wing and the reduction of calcification in the leg bones (24). Bone and delayed bone calcification due to contact with poisons were reported in children exposed to this poison. Few studies have been done concerning the toxic effect of external factors on growth plate closure and with mechanisms different from the effect of propiconazole (25).

Researchers showed that in desert rats subjected to intensive and long-term treatment with warfarin (from birth to eight months), excessive mineralization of the growth plate led to fusion and complete closure of the growth plate of the tibia and the stop of longitudinal growth (26). Height in these animals has become. Warfarin, along with defects in the synthesis of coagulation factors related to vitamin K in the liver, causes a decrease in the amount of mineralization inhibitory protein BGP, which requires vitamin K for synthesis), leading to excessive mineralization and closure of growth plaques. While the increase of serum

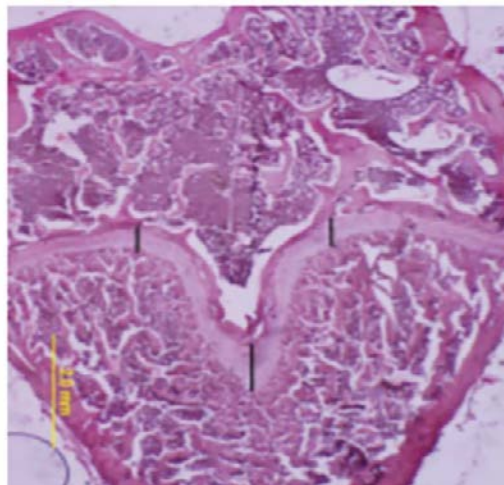
BGP in kidney patients or rats without kidney causes the growth plates to remain open (27).

Propiconazole causes a deficiency in the vitamin K function and a decrease in the level of BGP, followed by a disturbance in the inhibition of mineralization. Also, propiconazole has a destructive effect on the liver and hepatocytes. Propiconazole causes The fusion of the growth plate and a decrease in its width. This effect is different in each mouse compared to another mouse, which indicates the difference in the response of the body of people and is a personal medical approach. Of course, this hypothesis is against the oxidative effect of propiconazole on bone and cartilage cells (28). Growth plate areas have distinct morphological and biochemical characteristics controlled by growth factor signaling pathways. The destructive effect of propiconazole on mitochondrial membrane transmission, vacuolation, and swelling of mitochondria in the liver and heart of desert mice, destruction of cytochrome P450 and microsomes in human liver, changes in liver enzymes and biochemical indicators of hepatocytes has been proven (29).

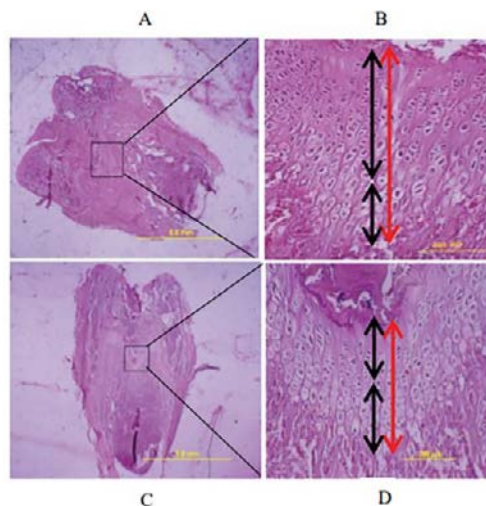
Mitochondria are the first organelles that are affected by propiconazole toxicity. Mitochondrial changes caused by propiconazole are an indicator of increasing the cell's need for energy to overcome toxicity effects (27-29). Considering the significant presence of mitochondria in the growth plate's multiplying area and these organelles' role in energy production, it can be hypothesized that the reduction of energy in these cells due to oxidative damage caused by propiconazole causes disruption in the process. Proliferation and the following stages of cell differentiation for the transition from proliferative state to mature and hypertrophied state. The destruction of other cell organelles membranes, which leads to a decrease in the synthesis of the intercellular matrix, can be a reason for the decrease in the width of the proliferating area in the present study. The hypertrophied area's width increase



**Fig1.** The growth plate of the lower femoral epiphysis of a rat and its different areas with E&H staining. A) growth plate with 10X magnification. B) magnification 100X. C) the region of proliferating cells and hypertrophied cells, 200X magnification.



**Fig2.** The growth plate cartilage of rat femoral epiphysis with E&H staining. Three selected areas for calculating the average growth plate width in the tested groups are marked with dark lines.



**Fig3.** A-D) tissue sections of the epiphyseal growth plate and proliferating and hypertrophied areas (one sample from six selected samples from each group) with hematoxylin-eosin staining. A, B) control group. C, D) Propiconazole group.

in the treatment with propiconazole can be attributed to this poisoning effect on the maturation and apoptosis of chondrocytes in this area and the disturbance in the process of chondroclastogenesis and calcification of the growth plate. In this case, propiconazole exerts its destructive effect by destroying the cell membrane of

organelles (30).

Using transgenic mice with defects in vitamin D absorption, researchers stated that the width of the growth plate of the tibia increased in these mutants. In the present study, propiconazole, while destroying osteoclasts and chondroclasts and inhibiting osteo/

chondroclastogenesis, has increased the hypertrophied area's width (31, 32). Achieving more accurate results requires conducting experiments at the cellular and molecular level (including measuring serum malondialdehyde levels as the final product resulting from lipid peroxidation of cells in bone tissue, measuring fluctuations in calcium, phosphorus, vitamin D metabolites, parathormone, sex hormones (FSH), LH, Estradiol (Testosterone), measuring biochemical markers of bone changes including osteocalcin, osteoprotegerin and alkaline phosphatase of bone tissue and bone resorption markers, measuring bone mineral deposition rate (MAR) Apposition Mineral and estimating the amount of spongy bone that develops along the growth plate should be done by three-dimensional color maps to observe the decrease or increase in the thickness of this area, which shows the degree of calcification of the growth plaque (32).

## CONCLUSION

Considering the histopathological effects of treatment with propiconazole in rat bone tissue, it is possible to point out the possibility of such cytotoxicity in farmers and people who are in regular contact with this compound and the need to take care and observe protective coatings to prevent the poison from entering the body. The body will lead to bone disorders and reduced or delayed skeletal growth due to their natural tendency to explore the surrounding environment by putting various objects in their mouths and being contaminated by direct contact with contaminated surfaces, floors, and air. In addition, the physiological characteristics of children, such as the high consumption of water, food, and air per unit of their body surface, can aggravate the risk and harm. It is also necessary to protect pregnant mothers. Based on the results from the histomorphometric studies, it can be concluded that propiconazole leads to a decrease in the width of immature rats' growth plates of the femoral epiphysis. Propiconazole can disrupt the longitudinal bone growth process and cause the growth plate to premature closure.

## REFERENCES

1. Upledger J. Taming osteoporosis. *Massage Today* 2005;5(11):36-41.
2. Fattahi E, Jorsaraei SG, Gardaneh M. The effects of carbaryl on the pituitary-gonad axis in male rats. *Iran J Reprod Med* 2012; 10(5):419-24.
3. Battaglin W, Sandstrom M, Kuivila K, Kolpin D, Meyer M. Occurrence of azoxystrobin, propiconazole, and selected other fungicides in US streams, 2005–2006. *Water Air Soil Pollut* 2011; 218: 307–22.
4. Hester S, Moore T, Padgett WT, Murphy L, Wood CE, Nesnow S. The hepatocarcinogenic conazoles:

Cyproconazole, epoxiconazole, and propiconazole induce a common set of toxicological and transcriptional responses. *Toxicol Sci* 2012; 127: 54–65.

5. Allen JW, Wolf DC, George MH, Hester SD, Sun G, Thai SF, et al. Toxicity profiles in mice treated with hepatotumorigenic and nonhepatotumorigenic triazole conazole fungicides: Propiconazole, triadimefon, and myclobutanil. *Toxicol Pathol* 2006;34 (7): 853-62.
6. Taxvig C, Hadrup N, Boberg J, Axelstad M, Bossi R, Bonefeld-Jørgensen EC, et al. In vitro-in vivo correlations for endocrine activity of a mixture of currently used pesticides. *Toxicol Appl Pharmacol* 2013;272(3):757-66.
7. Barton HA, Tang J, Sey YM, Stanko JP, Murrell RN, Rockett JC, et al. Metabolism of myclobutanil and triadimefon by human and rat cytochrome P450 enzymes and liver microsomes. *Xenobiotica* 2006; 36: 793–806.
8. Tully DB, Bao W, Goetz AK, Ren H, Schmid JE, Strader LF, et al. Gene expression profiling in liver and testis of rat to characterize the toxicity of triazole fungicides. *Toxicol. Appl. Pharmacol* 2006; 215: 260–73.
9. Skolness SC, Blanksma J, Cavallin J, Churchill E, Durhan K, Jensen R, et al. Propiconazole Inhibits Steroidogenesis and Reproduction in the Fathead Minnow (*Pimephales promelas*). *Toxicological Sciences* 2013;132(2), 284–97.
10. Li ZH, Zlabek V, Grabic R, Li P, Randak T. Modulation of glutathione-related antioxidant defense system of fish chronically treated by the fungicide propiconazole. *Comp Biochem Physiol C Toxicol Pharmacol* 2010;152(3):392-8.
11. Keramati V, Jamili S, Ramin M. Effect of diazinon on catalas antioxidant enzyme activity in liver tissue of rutilus rutilus. *Fisher Aquatic Sci* 2010;5(5):368-76.
12. Messarah M, Amamra W, Boumendjel A, Barkat L, Bouasla I, Abdennour C, et al. Ameliorating effects of curcumin and vitamin E on diazinon-induced oxidative damage in rat liver and erythrocytes. *Toxicol Ind Health* 2013;29(1):77-88.
13. Oksay T, Naziroglu M, Ergun O, Dogan S, Ozatik O, Armagan A, et al. N-acetyl cysteine attenuates diazinon exposure-induced oxidative stress in rat testis. *Andrologia* 2013;45(3):171-7.
14. Meneely GA, Wytenbach CR. Effects of the organophosphate insecticides diazinon and parathion on bobwhite quail embryos: skeletal defects and acetylcholinesterase activity. *J Exp Zool* 1989;252(1):60-70.
15. Yilmaz N, Yilmaz M, Altuntas I. Diazinon-induced brain toxicity and protection by vitamins E plus C. *Toxicol Ind Health* 2012;28(1):51-7.

16. Salehi M, Jafari M, Asgari A, Saleh Moghaddam M, Salimian M, Abbasnejad M, et al. Study of diazinon Effect on antioxidant enzymes and lipid peroxidation in rat's brain. *RJMS* 2010;17(70):15-23.
17. Misawa M, Doull J, Uyeki EM. Teratogenic effects of cholinergic insecticides in chick embryos. III. Development of cartilage and bone. *J Toxicol Environ Health* 1982;10(4-5):551-63.
18. Dahlgren JG, Takhar HS, Ruffalo CA, Zwass M. Health effects of diazinon on a family. *J Toxicol Clin Toxicol* 2004;42(5):579-91.
19. Ogutcu A, Uzunhisarcikli M, Kalender S, Durak D, Bayrakdar F, Kalender Y. The effects of organophosphate insecticide diazinon on malondialdehyde levels and myocardial cells in rat heart tissue and protective role of vitamin E. *Pesticide Biochem Physiol* 2006;86(9):93-8.
20. Saberi M, Gholizadehmoghadam S, Sharifzadeh M. Assessment of diazinone-induced oxidative stress on memory acquisition in male rats. *Daneshvar Med* 2010;17(87):19-28.
21. Baniadam A, Esmaeilzadeh S, Razi Jalali M, Khazali MR. Histopathological and paraclinical study of autogenous cancellous bone and bone marrow grafting for filling of segmental bone defect. *Jundishapur Sci Med J* 2006;5(1):412-20.
22. Kiernan JA. *Histological and Histochemical Methods: Theory and Practice*. 4th ed. Bloxham, UK: Scion, 2008.
23. Parfitt AM, Drezner MK, Glorieux FH, Kanis JA, Malluche H, Meunier PJ, et al. Bone histomorphometry: standardization of nomenclature, symbols, and units. Report of the ASBMR Histomorphometry Nomenclature Committee. *J Bone Miner Res* 1987;2(6):595-610.
24. Azarni M, Minaeii B, Mozaffari Z, Tahamtani Y. Histopathological effects of leaf extracts of *Trigonella foenum-graecum* on the development of the fetal rat long bone tissue. *J Dev Biol* 2008;1(1):50-8. [Persian]
25. Price PA, Williamson MK, Haba T, Dell RB, Jee WS. Excessive mineralization with growth plate closure in rats on chronic warfarin treatment. *Proc Natl Acad Sci U S A* 1982;79(24):7734-8.
26. Lee CS, Chen J, Wang Y, Williams JK, Ranly DM, Schwartz Z, et al. Coordinated tether formation in anatomically distinct mice growth centers is dependent on a functional vitamin D receptor and is tightly linked to three-dimensional tissue morphology. *Bone* 2011;49(3):419-27.
27. Ogutcu A, Uzunhisarcikli M, Kalender S, Durak D, Bayrakdar F, Kalender Y. The effects of organophosphate insecticide diazinon on malondialdehyde levels and myocardial cells in rat heart tissue and protective role of vitamin E. *Pesticide Biochem Physiol* 2006;86(2):93-8.
28. Panda DK, Miao D, Bolivar I, Li J, Huo R, Hendy GN, et al. Inactivation of the 25-hydroxyvitamin D 1alpha-hydroxylase and vitamin D receptor demonstrates independent and interdependent effects of calcium and vitamin D on skeletal and mineral homeostasis. *J Biol Chem* 2004;279(16):16754-66.
29. Piri-Gharaghie T. Polycystic ovary syndrome and genetic factors influencing its development: A review article. *Personalized Medicine Journal*. 2021 Dec 1;6(23):25-9.
30. Piri-Gharaghie T, Doosti A, Mirzaei SA. Identification of Antigenic Properties of *Acinetobacter baumannii* Proteins as Novel Putative Vaccine Candidates Using Reverse Vaccinology Approach. *Applied Biochemistry and Biotechnology*. 2022 Jun 7:1-23.
31. Ghajari G, Moosavi R. Evaluation of the effects of diazinon toxin on some reproductive parameters in male rats. 2022.
32. Yadollahi A, Ghajari G. Transgenic induction in *Sesamum indicum* with recombinant pBI121 expression construct containing CYP81Q1 and aroA genes using *Agrobacterium tumefaciens*. *Agricultural Biotechnology Journal*. 2022 Sep 23;14(3):223-42.