



DOI: 10.22034/pmj.2023.702079

Metastatic Malignancy Presenting as Thrombotic Thrombocytopenia Purpura; Report of Two Cases

Hamid Rezvani¹, Mehdi Tabarraee², Mojtaba Ghadyani², Seyed Amir Sheikholeslami³, Hamideh Rahmani², Soude Ramezan Nejad⁴, Aida Iranpour^{5*}

¹Associate professor, Department of Medical Oncology and hematology, Taleghani Hospital, Shahid Beheshti University of Medical Sciences, Tehran, Iran.

²Assistant professor, Department of Medical Oncology and hematology, Taleghani Hospital, Shahid Beheshti University of Medical Sciences, Tehran, Iran.

³Department of Medical Oncology and hematology, Imam hossein Hospital, Shahid Beheshti University of Medical Sciences, Tehran, Iran.

⁴Hematology and Oncology fellowship, Taleghani Hospital, Shahid Beheshti University of Medical Sciences, Tehran, Iran.

⁵Assistant professor, Iran university of medical sciences, Tehran, Iran.

*Corresponding author: Aida Iranpour, Assistant professor, Iran university of medical sciences, Tehran, Iran. Email: iranpouraida@gmail.com.

Submitted: 2022-12-09

Accepted: 2023-02-10

Keywords:

Thrombocytopenia
Gastric Cancer
Thrombotic Microangiopathy
Breast Cancer

©2023. Personalized Medicine Journal

Abstract:

Background

Cancer associated thrombotic microangiopathy (CA-TMA) is a rare diagnosis that while confronting a patient with evidence of microangiopathic hemolytic anemia and thrombocytopenia with normal ADAMTS13 enzyme activity, should be considered. Here we present two cases of cancer associated TMA; breast cancer and gastric cancer.

Case presentation

Case 1 was a 40-year-old man presented with abdominal pain, icterus and weight loss and laboratory tests revealed microangiopathic hemolytic anemia. He received 6 sessions of plasma exchange under diagnosis of thrombotic thrombocytopenic purpura. Bone marrow biopsy and immunohistochemistry revealed clusters of non-hematopoietic cells suggestive of gastrointestinal adenocarcinoma. Case 2 was a 51-year-old woman whose clinical history and laboratory tests were similar to case 1 except for a breast mass along with axillary lymphadenopathy. Bone marrow examination revealed clusters of non-hematopoietic cells and core needle biopsy revealed invasive lobular carcinoma.

Both patients were unresponsive to plasma exchange and case 1 unfortunately shortly died after diagnosis but case 2 is alive and survived after receiving chemotherapy.

Conclusion

Cancer associated TMA can rarely be seen as the first manifestation of a malignancy and causes a diagnostic dilemma for clinicians. The prognosis of CA-TMA is generally poor and initiating chemotherapy is the only reliable treatment option.

INTRODUCTION

Thrombotic thrombocytopenic purpura (TTP) is a thrombotic microangiopathy (TMA) which is divided into immune and hereditary based on ADAMTS 13 enzyme level. Hence, confronting a patient with evidence of microangiopathic hemolytic anemia and thrombocytopenia but with normal ADAMTS13 activity, other causes of TMA including cancer associated TMA (CA-TMA) should be considered. Since CA-TMA is a rare pathologic condition and is not responsive to plasma exchange therapy, it requires a broad and precise

differential diagnosis to achieve the most appropriate treatment (1). Here we present two cases of cancer associated TMA; breast cancer and gastric cancer.

Case presentation

Case 1

A 40-year-old male presented with abdominal pain, generalized weakness and icterus. Past medical history and drug history were unremarkable except for a history of 10-kilogram weight loss in the past month. In physical examination, drowsiness and icterus were

noted otherwise other examination were normal. Primitive laboratory test revealed severe anemia associated with thrombocytopenia, elevated LDH and abnormal liver function tests as shown in table 1.

Peripheral blood smear showed marked increase in schistocyte count and polychromasia suggestive of microangiopathic hemolytic anemia (MAHA) (Figure 1, Panel A). Under diagnosis of thrombotic thrombocytopenic purpura (TTP), emergent plasmapheresis along with dexamethasone were started. After 6 sessions, due to lack of response to primitive therapy and normal ADAMTS13 level, bone marrow aspiration and biopsy was performed that revealed infiltration of clusters of non-hematopoietic cells suggestive of metastatic malignancy (Figure 2, Panel A). IHC study of bone marrow was positive for CK7 and negative for CK20, CDX2, P63 and TTF1 suggestive of metastatic poorly differentiated CK7 positive carcinoma; therefore, gastrointestinal (GI) cancer particularly gastric adenocarcinoma was considered.

Chest and abdominopelvic CT revealed mediastinal and para-aortic lymphadenopathy. Pelvic MRI showed diffuse hyperintense signal in bone marrow of iliac crests suggestive of metastatic malignancy. Patient was scheduled for upper GI endoscopy and total colonoscopy but due to decreased level of

consciousness and severe thrombocytopenia could not be performed and patient died shortly after diagnosis.

Case 2

The patient was a 51-year-old woman who presented with weakness and drowsiness and past medical history and drug history were unremarkable. On physical examination, lumps in the left and right breasts of about 2 cm along with lymphadenopathy in the left axillary area were noted. As mentioned in case 1, primitive lab tests revealed anemia and thrombocytopenia with increased LDH (Table 1) while peripheral blood smear demonstrated 5% schistocytes and 2% nucleated RBC; findings that were suggestive of TMA.

Daily plasmapheresis was started but the response was disappointing by the end of 10 days. The LDH and nucleated RBC count were rising and platelet count and Hb reduced while ADAMS13 activity and antibody were normal. Bone marrow aspiration and biopsy revealed cluster of non-hematopoietic cells; therefore work-up for secondary causes of TTP was performed. After confirmation of the breast mass in ultrasound and mammography, core needle biopsy was done and IHC results of breast mass and BMB were in favor of invasive lobular carcinoma (ER=positive, PR=Positive, HER2=negative). Chest and abdominopelvic CT scan showed diffuse bone metastasis. After patient

Table 1. Laboratory results of patients.

Lab test	Case 1	Case 2	Lab test	Case 1	Case 2
WBC ($10^3/UL$)	3500	8400	AST (u/l)	55	64
Hb (g/dl)	7	7.5	ALT (u/l)	65	78
MCV (fL)	85	91	ALK.P (u/l)	672	477
MCH(Pgm)	31	30	Bilirubin total (mg/dl)	3	1.8
Platelet ($X1000/mm^3$)	25000	75000	Bilirubin direct (mg/dl)	0.4	0.2
LDH (u/l)	1600	5452	PTT (s)	30	33
Reticulocyte count (cells $X 10^9/L$)	5.5	3.5	INR	1	1.2

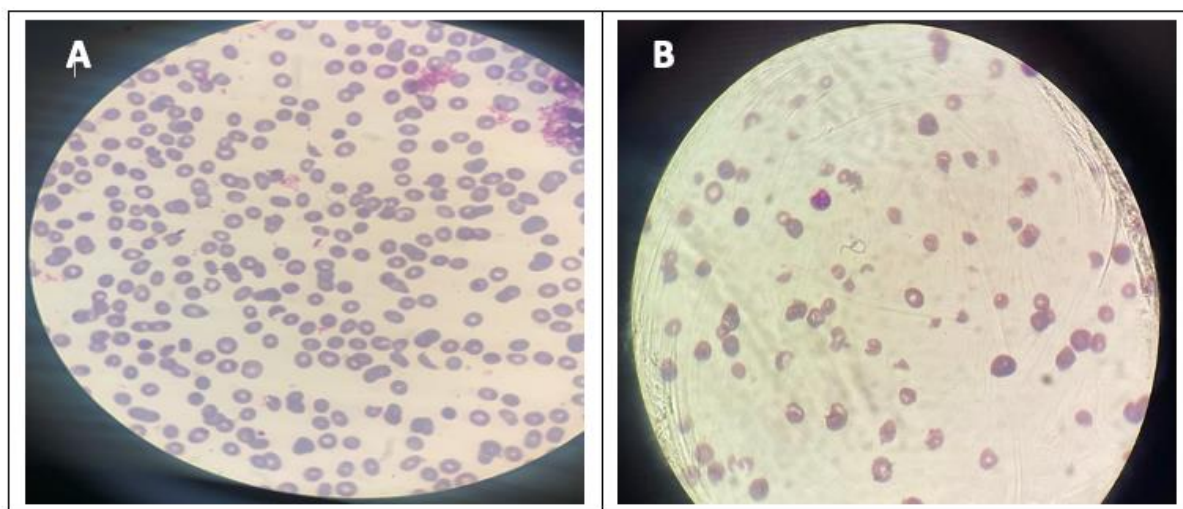


Fig 1. Peripheral blood smear patients revealed anemia and evidence of microangiopathic hemolytic anemia (Panel A, case 1; Panel B, Case2)

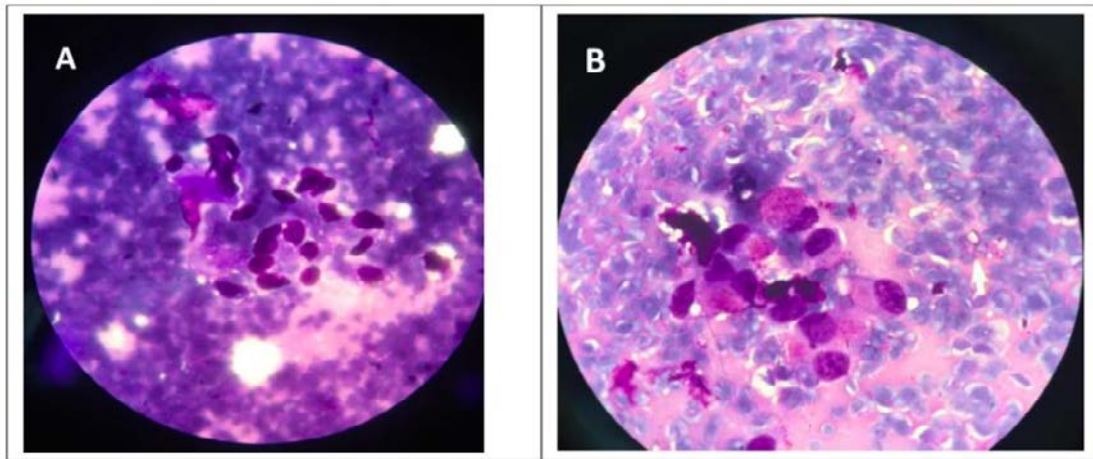


Fig 2. Bone Marrow aspiration revealed Clusters of non-hematopoietic cells in the marrow (Panel A, Case 1; Panel B, Case 2)

received the first course of AC regimen (Epirubicin and Cyclophosphamide) platelet count dramatically rose to ≥ 150000 and LDH was reduced and after 4 coarse the masses were 50 % decreased in size.

DISCUSSION

Cancer associated TMA (CA-TMA) can rarely be seen as the first manifestation of a malignancy and causes a diagnostic dilemma for clinicians. The most common malignancies associated with TMA are gastric, breast and prostate while lung and metastatic signet ring carcinoma of unknown origin have also been mentioned. The prognosis of CA-TMA is generally poor and initiating chemotherapy is the only reliable treatment option.

The exact pathogenesis of cancer associated TMA is unknown however some possible explanations are bone marrow infiltration with cancer and paraneoplastic syndrome (1). Other studies have suggested that fibrinoid necrosis of the bone marrow and tumor cell emboli could be other causes of CA-TMA while tumor-derived factors, procoagulants, and some chemotherapy agents are also considered causative agents of CA-TMA (2,3,4). The most common malignancies associated with TMA are gastric, breast and prostate (5) while lung and metastatic signet ring carcinoma of unknown origin have been mentioned in other studies. Signet ring carcinoma which is a subtype of mucin producing adenocarcinoma can arise from all organs but most common organs are stomach, breast and colon. Mucin probably has a direct detrimental effect on the endothelial cells leads to change their endothelial function and thus increases the production of ultra large von Willebrand factor multimers which could be another explanation of CA-TMA (6).

In comparison of idiopathic TTP with CA-TMA, a systematic review and report of ten patients based on Oklahoma TTP-HUS registry revealed that patients with malignancy are more often men with more frequent respiratory symptoms and longer duration of symptoms before diagnosis. Considering laboratory tests and treatment, patients with malignancy tend to have greater levels of LDH, less responding to plasma exchange and a higher mortality rate (7). Although

ADAMTS13 activity level of less than 10 % could differentiate these two entities from each other but severe ADAMTS13 deficiency of less than 5 % is not common in both groups (7).

Although diagnosis of TTP and urgent treatment with plasma exchange is critical in patients presenting with MAHA but response to plasma exchange is limited in patients with CA-TMA (8). Plasma exchange could even be harmful in patients with malignancy because it may cause microcirculatory damage and this may enhance microthrombi formation (9). Furthermore, avoidance of unnecessary plasma exchange in these patients will decrease the additional risk of plasma exchange complications such as catheter infection, sepsis, venous thrombosis and pericardial tamponade (10). The ultimate treatment of CA-TMA is systemic chemotherapy, thus review of the literature revealed that despite initiating treatment early in the course of the disease, most patients die within few weeks and the most common cause of death was infection.

In conclusion, the prognosis of CA-TMA is generally poor and initiating chemotherapy is the only reliable treatment options.

Acknowledgment

None

Conflict of interests

The authors declare no conflict of interest

REFERENCES

1. Baysal M, Alkış N, Tosun S. Signet ring cell carcinoma metastasis in the bone marrow accompanied by cancer related thrombotic microangiopathy as a first presentation. *Nigerian Journal of Clinical Practice*. 2022 Feb 1;25(2):211.
2. Shin SY, Park H, Chae SW, Woo HY. Microangiopathic hemolytic anemia as the first manifestation of metastatic signet ring cell carcinoma of unknown origin: a case report and review of literature. *The Korean Journal of Laboratory Medicine*. 2011 Jul 1;31(3):157-61.
3. Hilgard P and Gordon-Smith EC. Microangiopathic haemolytic anaemia and experimental tumour-cell emboli. *Br J Haematol* 1974;26:651-9.
4. Caine GJ, Stonelake PS, Lip GY, Kehoe ST. The hypercoagulable state of malignancy: pathogenesis and

- current debate. *Neoplasia* 2002;4:465-73.
5. Lechner K, Obermeier HL. Cancer-related microangiopathic hemolytic anemia: Clinical and laboratory features in 168 reported cases. *Medicine (Baltimore)* 2012;91:195-205.
 6. Spoormans I, Altintas S, Van den Brande J, Luijckx A, Vermorken JB. Purpura in a patient with disseminated breast cancer: a rapidly progressive cancer-related thrombotic thrombocytopenic purpura. *Annals of oncology*. 2008 Jun 1;19(6):1204-7.
 7. Francis KK, Kalyanam N, Terrell DR, Vesely SK, George JN. Disseminated malignancy misdiagnosed as thrombotic thrombocytopenic purpura: a report of 10 patients and a systematic review of published cases. *The Oncologist*. 2007 Jan;12(1):11-9.
 8. Masias C, Vasu S, Cataland SR. None of the above: Thrombotic microangiopathy beyond TTP and HUS. *Blood* 2017;129:2857-63.
 9. Vasko R, Koziolok M, Fuzesi L, Konig F, Strutz F, Muller GA. Fulminant plasmapheresis-refractory thrombotic microangiopathy associated with advanced gastric cancer. *Ther Apher Dial* 2010;14:222-5.
 10. Howard MA, Williams LA, Terrell DR et al. Complications of plasma exchange in patients treated for clinically suspected thrombotic thrombocytopenic purpura-hemolytic uremic syndrome. III. An additional study of 57 consecutive patients, 2002–2005. *Transfusion* 2006;46: 154–156.