



Correlation between Inflammatory Aortic Disease and Rheumatoid Arthritis Based on Personalized Medicine

Babak Farshid¹; Hamidreza Kabiri^{2*}

¹Biotechnology Research Center, Islamic Azad University, Shahrekord Branch, Shahrekord, Iran.

²Young Researchers and Elite Club, Shahrekord Branch, Islamic Azad University, Shahrekord, Iran.

DOI: 10.22034/pmj.2023.705461

*Corresponding author: Hamidreza Kabiri, Young Researchers and Elite Club, Shahrekord Branch, Islamic Azad University, Shahrekord, Iran. Email: sabaco92@yahoo.com.

Submitted: 2023-03-15

Accepted: 2023-05-29

Keywords:

Rheumatoid arthritis
Rheumatoid vasculitis
Inflammatory Aortic Disease

©2023 Personalized Medicine Journal

Abstract:

The synovial joints are most affected by the systemic autoimmune inflammatory condition known as rheumatoid arthritis (RA). A unique and underappreciated link exists between rheumatoid vasculitis (RV), an extra-articular symptom of RA, and Inflammatory Aortic Disease (aortitis). In this article, we describe the case of a 64-year-old lady who had RA-associated aortitis and conducted a literature search on the condition. Patients with RA-associated aortitis received an average oral steroid dosage of 40.2 mg/day of prednisolone (PSL). Due to the patient's RV-related symptoms, including epidermal ulceration, a significant rheumatoid factor titer, and a modest PSL dosage significantly alleviated the clinical features, it was assumed that RV also caused our patient's aortitis. Early identification and the start of therapy are crucial since RA-associated aortitis may be lethal if left untreated.

INTRODUCTION

The aortic wall becomes inflamed when Inflammatory Aortic Disease (aortitis) occurs (1). The condition is uncommon and perhaps fatal. According to statistics, there are only 1-3 new instances of aortitis per million individuals per year in the United States and Europe. Ages 10 to 40 are the most prevalent in which aortitis occurs (1, 2).

Aortitis is an inflammation that attacks major arteries more frequently than other vasculitides. Ankylosing spondylitis (AS), Behçet's illness, rheumatic diseases (RA), and lupus erythematosus systemic are autoimmune conditions linked to aortitis. Additionally, infectious disorders like syphilis and TB are linked to aortitis (3). Inflammation is a common factor in the causes of both rheumatic and heart diseases. The elevated concentrations of inflammatory response that classify rheumatic illnesses offer a «natural experiment» to help understand the processes by which inflammatory response expedites heart disease (4). The most prevalent rheumatic disease, rheumatoid arthritis (RA), has the most thoroughly researched associations with heart disease (5, 6).

An auto-immune and structural inflammatory condition, rheumatoid arthritis primarily affects the synovial fluid. RA patients can have extra-articular symptoms such rheumatoid vasculitis (RV). Once

vasculitis with major clinical symptoms was first recorded in RA patients in the 1960s, the idea of RV began to take shape. Around 90percent of RA patients with RV show skin symptoms; other clinical signs of vasculitis involve weakness, weight loss, skin irritation, cutaneous bleeding ulcers, necrosis, neuropathic pain, and abdominal infarction (7, 8).

The risk of cardiovascular disease (CVD) is increased by rheumatoid arthritis (RA). In RA patients, atherosclerosis progresses more quickly, increasing mortality. Chronic systemic inflammation may hasten the progression of atherosclerosis in RA patients due to the exact pathophysiological mechanisms between an inflammatory synovial membrane and an atherosclerotic plaque. Previous research has shown that atherosclerosis is more common in the RA group than in the general population (9, 10). RA patients' joints may be assessed with 18F-fluorodeoxyglucose (FDG) positron emission (PET)/computed tomography (CT). Since the 18F-FDG absorption represents the glucose production of monocytes in atherosclerotic plaque, FDG PET/CT has also been frequently utilized to assess atherosclerosis. FDG PET/CT is a very reliable technique for detecting arterial inflammation, however, there are few publications on how well it works to evaluate aortic inflammatory response in RA patients (9, 10).

Aortitis and RV rarely coexist, and this connection is not well known. A researcher first identified RA aortitis, and earlier studies have noted it. According to Miller et al., 45 incidents of active non-infectious aortitis were observed between 513 successive ascending aortic resections, and 4% of those patients had RA (11, 12). In this work, we report a case of RA-related aortitis and conduct a systematic review.

CASE DESCRIPTION

Patient details

We described a case of RA-related aortitis and examined 31 cases from 10 papers published on the condition. We searched PubMed for reported situations of RA aortitis using the words “osteoarthritis,” “autoimmune disease,” “aortitis,” and “portal vein vasculitis.” We assessed pathology, laboratory results, human lymphocytes antigen (HLA) pattern, age at RA and aortitis emergence, the time between RA and aortitis emergence, and other clinical findings.

Diagnostic assessment

A 64-year-old lady who had been experiencing discomfort and inflammation in the tiny bones of her arms for the previous two months went to the hospital. The experimental test results showed elevated levels of C-reactive protein (CRP; 1.91 mg/L) and erythrocyte sedimentation rate (ESR; 29 mm/h). Her anti-cyclic citrullinated protein (anti-CCP) amount was 57.3 IU/mL, and her inflammatory arthritis factor (RF) amount was 238.1 IU/mL. The nonspecific interlayer pneumonia (NSIP) sequence on the subsequent radiograph indicated interlayer pneumonia, which was provocative of RA. The patient was identified as having RA based on these findings. Salazosulfapyridine (SASP) at 750 mg/day was used to treat her RA, which helped with her clinical signs and test results. However, according to the clinical lesson, SASP was found to be insufficiently efficient after a year of treatment; as a result, 3 mg/day of tacrolimus was added to the regimen. Her articular signs and the inflammatory research results in the lab subsided after that.

After receiving treatment, she visited an outpatient facility with a 38–39°C fever, a cough, and top back problems that had been prevalent for a week. Additionally, a month earlier, she had established a skin ulcer on her right patella. During the sample analysis, inflammatory mediators with elevated levels were discovered to be ESR 108 mm/h and CRP 15.04 mg/dL. Her rheumatoid factor (RF) and matrix metalloproteinase-3 (MMP-3) amounts were 124.6 IU/L and 2,071.0 IU/mL, respectively. The C3 and C4 levels are decreased to 122.0 and 12.7 mg/dL, respectively. Antibodies against nuclear, DNA, Sm, RNP, and La were all negative. Antinuclear antibodies, perinuclear anti-neutrophil cytoplasmic antibodies (C-ANCA),

and cytoplasmic pattern anti-neutrophil cytoplasmic antibodies (C-ANCA) were all negative. Three various sets of clinical specimens came back empty. A negative result was obtained for the galactomannan antigen, -D-glucan, QuantiFERON test, rapid plasma reagin test (RPR), and Treponema pallidum haemagglutination assay (TPHA). An echocardiogram revealed no indications of vegetation in her heart. A thoracic-abdominal computed tomography (CT) was performed to investigate the persistently elevated inflammatory markers. The results showed no signs of pneumonia but that the left subclavian artery, brachiocephalic artery, ascending and descending aorta, and aortic arch were all dilated. Atherosclerosis, aneurysms, or any risk variables for bacterial aneurysms were also not present. Fluorodeoxyglucose-positron emission tomography/CT (FDG-PET/CT) later demonstrated a significant abnormal tracer uptake consistent with the CT-detected dilated aortas (Figure 1A). Additionally, FDG uptake was seen in the knee skin ulcer (Figure 1B). Despite having the ulcer’s skin biopsied, no clear vasculitis findings were found (Figure 1C).

Antibacterial therapy was first started, but it did not affect the fever, the elevated ESR and CRP, or the radiographic evidence of aortic dilation. Prednisolone [PSL, 30 mg/day) was started seven days after the antibiotic therapy because we suspected autoimmune aortitis. One day after beginning steroid medication, the patient’s fever subsided, she no longer had upper back discomfort, and the inflammatory markers started to fall.

The skin ulcer on the right knee also significantly improved. Within a month of beginning the steroid therapy, these abnormalities returned to normal. Following the start of steroid therapy, on day 28, a follow-up CT revealed that the aortic dilation was gone entirely (Figure 2). Additionally, on day 42 following the start of the steroid treatment, FDG-PET showed that the aorta’s abnormally high level of intense tracer uptake had also stopped (Figure 2). The patient was released after the prednisolone dosage was decreased to 27.5 mg daily.

Overview of relevant literature and evaluation of our case

We looked at 31 scenarios from 10 RA aortitis studies and found one instance of aortitis that was RA-related. The patients’ average ages at the time of RA and aortitis diagnoses were 48±10.2 and 51±11.3, respectively. The median time between RA onset and aortitis’s appearance was 6.0–7.07 years. Extra aortic arteritis involvement was found in 10/25 cases (53.1%).

According to the pathological results of RA aortitis, granulation tissue, granulocytes, and atherosclerosis were discovered in 6/14 patients, 3/14 cases, and 14/18 points, respectively. Regarding the laboratory results,

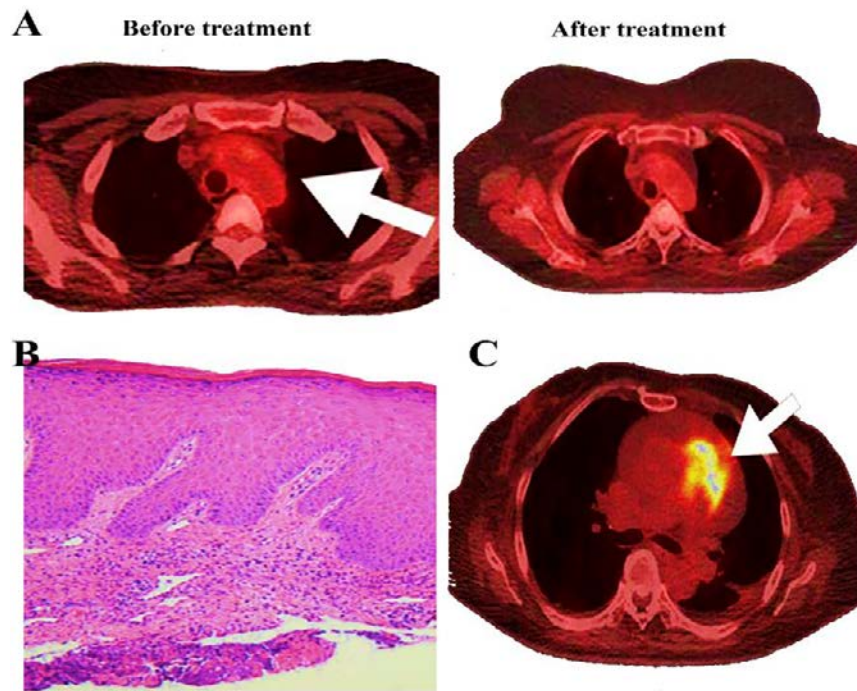


Fig1. Pathological and PET/CT results of the epidermal ulceration; FDG-PET/CT results of aortitis prior and during steroid treatment. A) The left subclavian artery, brachiocephalic artery, ascending aorta, and aortic arch showed enhanced tracer absorption on FDG PET/CT. B) A minor lymphocytic infiltration was seen in the superficial epidermis after a biopsy of the ulcer's margin, but no overt signs of vasculitis were found. C) An ulcer with enhanced tracer absorption on FDG PET/CT suggested inflammation.

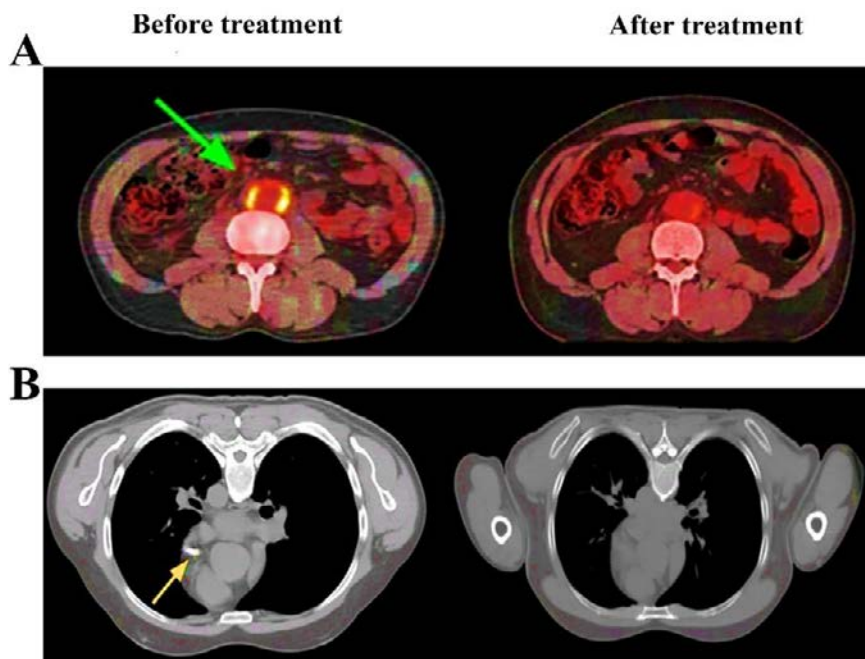


Fig2. Aortitis in the thorax as shown on contrast-enhanced CT prior to and following steroid treatment. A) Thoracic especially in comparison CT imaging showed thickness of the vessel walls at the region of the aortic arch and aortic arch, left anterior artery, and left descending aorta artery prior to steroid medication. B) The swelling of the aorta wall has totally vanished after steroid medication.

RF was positive in 20/23 patients, and rheumatoid lesions were discovered in 11/21 instances. In the individuals diagnosed whose doses were disclosed, the average oral steroid dosage for aortitis was 49.1 mg/day PSL. Two patients received intravenous steroids in addition. One individual had a single round of steroid

pulse medication with methyl PSL 250 mg followed by a post-treatment PSL dosage of 40 mg. Another patient received intravenous PSL 100 mg and intravenous cyclophosphamide (IVCY). Before the emergence of aortitis, there were many RA treatments. Our individual was older than some previously described since the

prodromal symptoms of RA and aortitis, in this case, happened at ages 60 and 63, respectively. According to other studies, at least half of the individuals had vasculitis symptoms other than aortitis, and these symptoms were indicative of a severe case of RA. Our patient experienced a cutaneous ulcer simultaneously, consistent with our findings. PSL was given as therapy at a dosage of 30 mg daily, which is equivalent to the average recorded steroid dose.

DISCUSSION

RA-related aortic abnormal cells have been documented in case reports, but they are still relatively uncommon complications. Contrarily, AS-related aortitis is well known, and early literature suggests that, at one point, it was challenging to distinguish between aortitis brought on by RA and AS (13). Although the two have related pathophysiological observations, it is relatively simple to distinguish between aortitis in RA and that in AS, depending on the medical course, laboratory findings, and radiological experiments (14). Findings in both AS and RA aortitis include lymphoplasmacytic infiltration, necrosis of the medial smooth muscle cells, and loss of elastic fibers. A rheumatoid granuloma, in contrast, is a distinctive feature that can be easily distinguished and is only present in aortitis linked to RA (15). Additionally, many cases of autoimmune aortitis are caused by TKA and GCA. According to the 2012 CHCC, it is challenging to distinguish between the pathological findings of the aorta in these two diseases (16). There have been reports of RA and TKA occurring simultaneously, but like the aortitis in AS, it is challenging to tell whether the aortitis is caused by RA or TKA based on pathology (17).

According to reports, small and medium-sized vascular vasculitis is the leading cause of RV. However, several accounts claim that RV happens in the aorta, a large channel. Individuals with severe RA are substantially more likely to have RA-associated aortitis, suggesting a link to RV. High-titer rheumatoid factors, a duration lasting a year or more significant after the commencement, bone erosions, and rheumatoid lesions have all been described as risk factors for the development of RV. We saw the first two characteristics in our case (18).

Additionally, our patient showed signs of a skin ulcer, seen in almost 90% of individuals with RV. The patient's skin biopsy, however, revealed no signs of vasculitis. This could be because the biopsy specimen was taken from a very superficial spot; vasculitis would have been seen if the higher epidermal layer had been tested (19). According to the following considerations, vasculitis may have also been the root cause of the patient's deep skin ulcer: "no findings implying a history of trauma,

pressure ulcer, or infection"; "vasculitis is the primary reason presumed when a deep skin ulcer is noticed," as it was in this case; "FDGPET/CT demonstrates FDG uptakes at the ulcer location, implying inflammatory response"; and "the patient reacted well to steroid injections." The Scott and Bacon requirements for RV would be satisfied if our patient's skin ulcer were caused by vasculitis, and it is very plausible that our patient's aortitis was related to RV (20). The genetic study has identified HLA-DRB1*0401 as a potential cause for RV, and around 5% and 21% of RV individuals are homozygous or heterozygous and heterozygotes of this gene, respectively. HLA-B51 and B52 were found in our instance, but not HLA-DRB1*0401 Behçet's syndrome and TKA are linked to HLA-B51 and HLA-B52, respectively. These conditions have a connection to aortitis.

Our individual did not exhibit the related symptoms of vaginal ulcers, ocular diseases such as uveitis, or aphthous mouth ulcers. Hence Behçet's illness was not diagnosed in her case. Given that our case's aortitis started at 64 years old and that TKA often affects people under 50, it seems improbable that it was TKA. In addition, our individual had interstitial pneumonia, indicative of RA, and fulfilled the 2010 ACR/EULAR criterion (21). Clinical signs of aortitis in our individual were significantly relieved by oral PSL at a dosage of 30 mg per day. According to our research, the typical PSL dosage for treating aortitis is 46.3 mg; as a result, aortitis might be treated with a moderate PSL dosage. However, researchers reported that ten RA-associated aortitis clients died from congestive cardiac failure, aortic exploding, and acute coronary syndrome. In addition, most of these individuals were not treated for any steroid or immunosuppressive therapy because they were not identified with aortitis until after they passed. These instances indicate that RA-associated aortitis is a severe condition that, if neglected, may be deadly (22).

CONCLUSION

We described a woman with high-titer rheumatoid factor and epidermal ulceration as RV symptoms. Aortitis was also present, and a modest dosage of PSL significantly alleviated her clinical signs. Because RA aortitis may be deadly if ignored, it is crucial to identify and treat it early.

REFERENCES

1. Marvisi C, Buttini EA, Vaglio A. Aortitis and periaortitis: the puzzling spectrum of inflammatory aortic diseases. *La Presse Médicale*. 2020 ;Apr 1;49(1):104018.
2. Piri-Gharaghie T, Doosti A, Mirzaei SA. Identification of antigenic properties of *Acinetobacter baumannii* proteins as novel putative vaccine candidates using reverse vaccinology approach. *Applied Biochemistry and*

- Biotechnology. 2022; Oct;194(10):4892-914.
3. Crowson CS, Liao KP, Davis III JM, Solomon DH, Matteson EL, Knutson KL, Hlatky MA, Gabriel SE. Rheumatoid arthritis and cardiovascular disease. *American heart journal*. 2013; Oct 1;166(4):622-8.
 4. Trzeciak P, Herbet M, Dudka J. Common Factors of Alzheimer's Disease and Rheumatoid Arthritis—Pathomechanism and Treatment. *Molecules*. 2021; Oct 5;26(19):6038.
 5. Zarinnezhad A, Shahhoseini MH, Piri Gharaghie T. Evaluating the relative frequency of fungal infections in the serum of patients with multiple sclerosis and healthy subjects using PCR. *Biological Journal of Microorganism*. 2021; Mar 21;10(37):37-50.
 6. Piri Gharaghie T, Sadat Shandiz SA, Beiranvand S. Evaluation of silver nanoparticles effects on bla-per1 gene expression for biofilm formation in isolates of antibiotic-resistant *Acinetobacter Baumannii* by real time PCR method. *Cellular and Molecular Research (Iranian Journal of Biology)*. 2022 ;Jun 22;35(2):349-66.
 7. Bauer ME. Accelerated immunosenescence in rheumatoid arthritis: impact on clinical progression. *Immunity & Ageing*. 2020 ;Dec;17(1):1-4.
 8. Piri Gharaghie T, Sadat Shandiz SA. The inhibitory effects of silver nanoparticles on bap gene expression in antibiotic-resistant *Acinetobacter baumannii* isolates using real-time PCR. *Journal of Ilam University of Medical Sciences*. 2018; Nov 15;26(4):175-85.
 9. Trang DA, Okamura K, Suto T, Sakane H, Yonemoto Y, Nakajima T, Tsushima Y, Chikuda H. Do biologic therapies reduce aortic inflammation in rheumatoid arthritis patients?. *Arthritis Research & Therapy*. 2021; Dec;23(1):1-7.
 10. Piri-Gharaghie T. Polycystic ovary syndrome and genetic factors influencing its development: A review article. *Personalized Medicine Journal*. 2021; Dec 1;6(23):25-9.
 11. Miller DV, Isotalo PA, Weyand CM, Edwards WD, Aubry MC, Tazelaar HD. Surgical pathology of noninfectious ascending aortitis: a study of 45 cases with emphasis on an isolated variant. *The American journal of surgical pathology*. 2006; Sep 1;30(9):1150-8.
 12. Beiranvand S, Doosti A, Mirzaei SA. Putative novel B-cell vaccine candidates identified by reverse vaccinology and genomics approaches to control *Acinetobacter baumannii* serotypes. *Infection, Genetics and Evolution*. 2021; Dec 1;96:105138.
 13. García-Martínez A, Prieto-González S, Giménez PA, Espígol-Frigolé G, Hernández-Rodríguez J, Cid MC. Aortitis and aortic aneurysm in systemic vasculitis. In *Etiology, Pathogenesis and Pathophysiology of Aortic Aneurysms and Aneurysm Rupture 2011*; Jul 27. IntechOpen.
 14. Ferrera C, Vilacosta I, Cabeza B, Cobiella J, Martínez I, Saiz-Pardo Sanz M, Bustos A, Serrano FJ, Maroto L. Diagnosing aortic intramural hematoma: current perspectives. *Vascular Health and Risk Management*. 2020; Jun 8:203-13.
 15. Töpel I, Zorger N, Steinbauer M. Inflammatory diseases of the aorta: Part 1: non-infectious aortitis. *Gefasschirurgie*. 2016;21(Suppl 2):80.
 16. Hur JH, Chun EJ, Kwag HJ, Yoo JY, Kim HY, Kim JJ, Lee KW. CT features of vasculitides based on the 2012 International Chapel Hill Consensus Conference revised classification. *Korean Journal of Radiology*. 2017; Oct 1;18(5):786-98.
 17. Moittié S, Sheppard MN, Thiele T, Baiker K. Non-Infectious, Necrotizing and Granulomatous Aortitis in a Female Gorilla. *Journal of Comparative Pathology*. 2020; Nov 1;181:7-12.
 18. Nikol S, Mathias K, Olinic DM, Blinc A, Espinola-Klein C. Aneurysms and dissections-What is new in the literature of 2019/2020-a European Society of Vascular Medicine annual review. *VASA*. 2020; Aug 27.
 19. Sangolli PM, Lakshmi DV. Vasculitis: A checklist to approach and treatment update for dermatologists. *Indian dermatology online journal*. 2019; Nov;10(6):617.
 20. Quintana-Castanedo L, Feito-Rodríguez M, Fernández-Alcalde C, Granados-Fernández M, Montero-Vega D, Mayor-Ibarguren A, de Lucas-Laguna R. Concurrent chilblains and retinal vasculitis in a child with COVID-19. *Journal of the European Academy of Dermatology and Venereology*. 2020; Dec;34(12):e764.
 21. Algahtani H, Shirah B, Khafaji R, Algahtani S. Novel Heterozygous Variants in the HLA-DRB1 Gene in a Saudi Family With Early-Onset Familial Multiple Sclerosis: Therapeutic Failure and Success. *International Journal of MS Care*. 2022; May 1;24(3):100-3.
 22. Akebo H, Sada R, Matsushita S, Ishimaru H, Minoda S, Miyake H, Tsugihashi Y, Hatta K. Lupus aortitis successfully treated with moderate-dose glucocorticoids: a case report and review of the literature. *Internal Medicine*. 2020; Nov 1;59(21):2789-95.